

Complete rehabilitation of an unsatisfactorily restored mandible

Two-piece implants and the alveolar ridge-splitting technique

Dr Michael Leistner, Germany

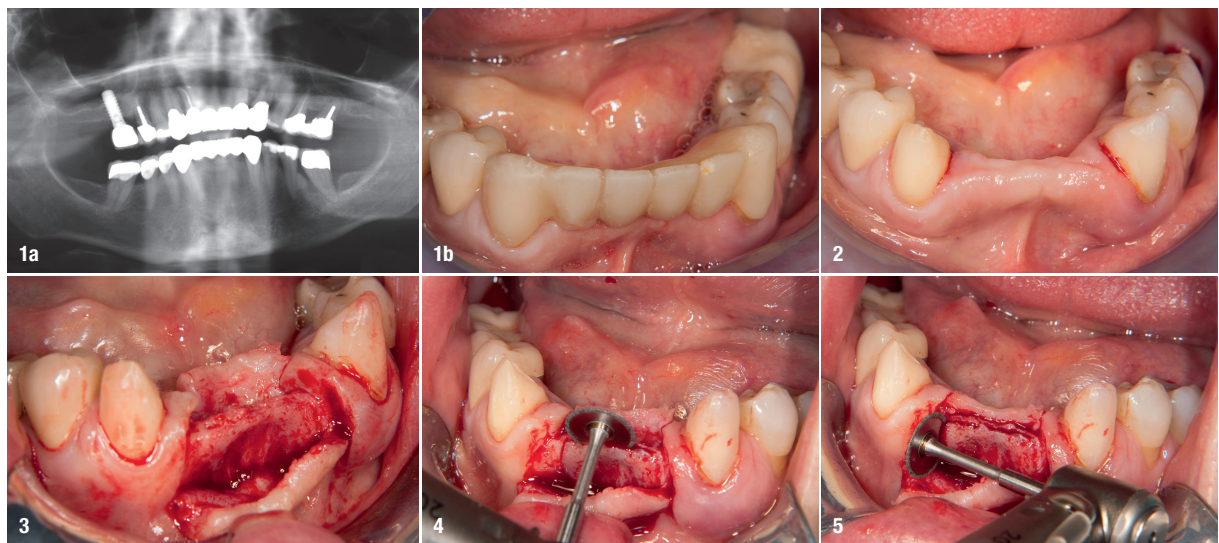
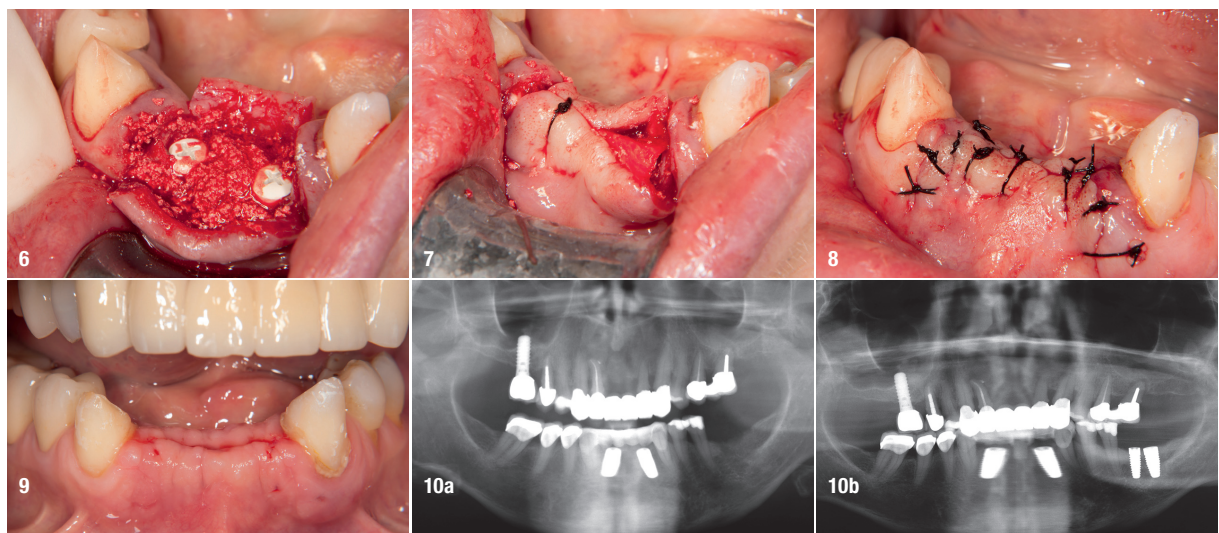


Fig. 1: Initial situation: radiograph (a) and clinical view (b). **Fig. 2:** Intra-oral situation after tooth removal and completed tissue healing. **Fig. 3:** Opened and mobilised flap and exposure of the residual bone. **Fig. 4:** Sagittal cut to split the bone ridge using a small fine-grained diamond disc. **Fig. 5:** Vertical cuts at the outer limits of the bone flap. **Fig. 6:** Situation after spreading of the bone, implant placement and filling of the remaining defects with autogenous bone chips. **Fig. 7:** Subsequently, covered with a removable membrane, the flap is repositioned and fixed with sutures. **Fig. 8:** Wound closure after completion of the surgery. **Fig. 9:** Clinical situation after two weeks and suture removal. **Fig. 10:** OPG four weeks after bone splitting and placement of the two Zeramex XT implants in regions #32 and 42 (a) and three months after implant insertion in the posterior region (regions #36 and 37; b)

Case description

A 65-year-old female patient presented herself with insufficient fillings, crowns and bridges in the mandible (Fig. 1). The first molar on the left side showed advanced mobility (Grade III). The bridgework in the anterior region

was to be replaced by single-tooth crowns on the remaining natural teeth and a bridge supported by two implants in regions #32 and 42 was planned. By using the bone-splitting technique, the local bone in this area was to be enhanced (Figs. 2–5). After removal of the hopeless teeth #36 and 37 and sub-



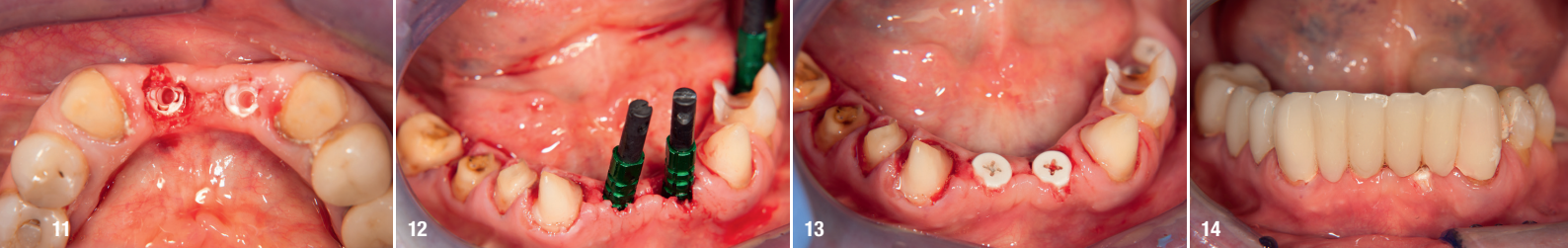


Fig. 11: Both anterior implants were uncovered using a tissue trimmer (NTI-Kahla), retrieval of the healing caps. **Fig. 12:** After preparation of the remaining natural teeth, an impression was taken including impression copings on the implants (open-tray technique). **Fig. 13:** Healing abutments were inserted on to the implants for soft-tissue adaptation. **Fig. 14:** Provisional restoration inserted.

sequent bone healing, two ceramic implants were to be placed in these regions. In addition, all remaining natural teeth required new prosthetic restoration with crowns.

Materials

The implants used in this case were Zeramex XT implants (Dentalpoint) with diameters of 4.2mm (regular base) and 5.5mm (wide base) and a length of 10.0mm. In addition, maxresorb inject (botiss biomaterials) and a Jason membrane (botiss biomaterials) were used as part of the bone grafting procedure to cover the bony structures (Figs. 6–14).

Conclusion

After more than ten years of working with two-piece ceramic implants and with more than 1,100 Zeramex implants of several types and generations having been placed, the author feels confident in using this technology in conjunction with ceramic implants restored with bridges. In his daily routine, the Zeramex XT implant with its internal geometry in combination with the carbon fibre-reinforced high-performance PEEK screw (Vicarbo screw) allows patient-specific prosthetic restorations, including bridgework and removable dentures, with reliable long-term success, including stable aesthetic outcomes (Figs. 15–19).

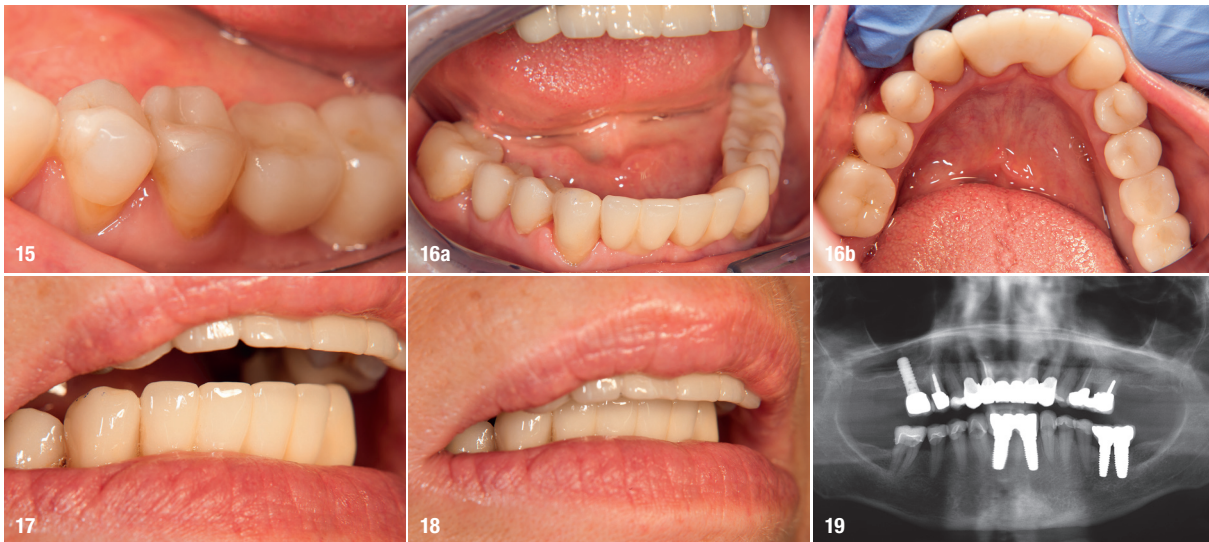


Fig. 15: Delivery of the final posterior superstructures. **Fig. 16:** Definitive anterior bridgework: anterior view (a) and occlusal view (b). **Figs. 17 & 18:** Image of the harmonious interaction of the prosthetic restoration with the lip line. **Fig. 19:** X-ray to control the fit of the prosthetic restorations after four months.

Practical relevance

Alveolar ridge-splitting and expansion techniques are suitable and well-established methods for managing narrow residual bone with relatively minor effort.¹ Different techniques and utilisation of various types of instruments are described in the literature, and only minor differences between them are reported regarding survival of the implants.^{2,3} Furthermore, study reviews have revealed a low rate of intra- and postoperative complications, such as buccal wall fracture, which requires careful preparation of the ridge and prudent selection of patients.⁴ Based on the clinical experience of the author, the technique employed for this case works particularly well in combination with ceramic implants owing to their high biocompatibility and material properties.⁵

about the author



Dr Michael Leistner is a Germany-based dentist specialized in dental implantology, focusing particularly on the use of ceramic implants. He runs a private practice in the city of Merzhausen in Germany.

contact

Dr Michael Leistner
info@dent-design.de

